

A photograph of medical professionals in a clinical setting. In the foreground, an older man on the left and a younger woman on the right, both wearing white lab coats over blue scrubs, are looking down with focused expressions. In the background, two other individuals are visible but out of focus. The overall atmosphere is professional and studious.

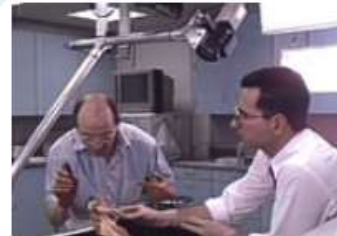ACLAND'S VIDEO ATLAS OF
HUMAN ANATOMY

Cos'è Acland's Video Atlas of Human Anatomy?

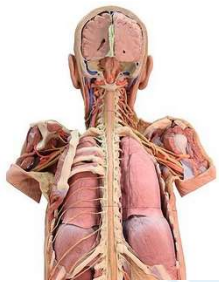
- Sviluppato e narrato dal Dr. Robert (Bob) Acland e dal suo team presso la School of Medicine dell'Università di Louisville.
- 5 Volumi con più di 300 video di macro anatomia rotazionale in 3D con veri campioni da cadavere, accompagnati da una narrazione chiara e strutture etichettate per rafforzare l'apprendimento e la revisione.
- È una piattaforma basata sui browser web che può essere visualizzata sui computer. L'interfaccia è ottimizzata per iPad e altri tablet, nonché smartphone.
- I video mostrano strutture in movimento - muscoli, tendini e articolazioni - che eseguono i movimenti naturali in vita.
- Quiz interattivi per aiutarti a valutare la padronanza dell'anatomia.
- La piattaforma è disponibile in inglese e spagnolo.
- La piattaforma supporta più opzioni di accesso e autenticazione.

ULTERIORI INFORMAZIONI e LA STORIA DEL PROGETTO DI ACLAND:

<https://aclandanatomy.com/public/about.aspx>



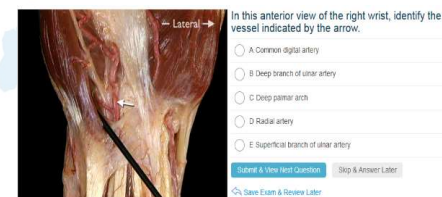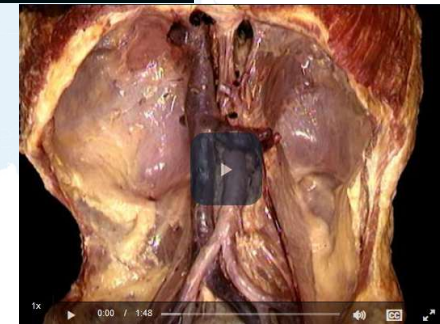
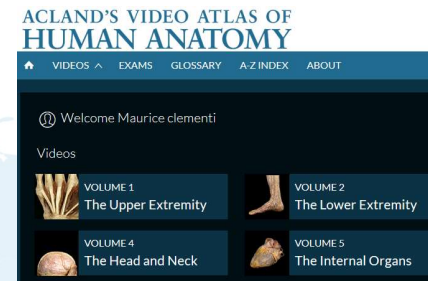Per chi è questo prodotto?



















- **Studenti di medicina e odontoiatria.** Ottima introduzione per coloro che studiano nel primo anno. Per quegli studenti che non hanno accesso alle strutture di dissezione, il Video Atlas offre un apprezzamento del vero corpo umano e una comprensione diretta della meccanica dell'anatomia funzionale.
- **Praticanti di medicina.** Praticanti chirurghi e medici apprezzano il Video Atlas come un modo rapido per rinnovare le conoscenze anatomiche e per aiutare i loro pazienti a comprendere una patologia, una lesione o una procedura.
- **Studenti nelle professioni sanitarie.** Il video Atlas è ampiamente utilizzato da studenti e insegnanti in infermieristica, terapia fisica e occupazionale, kinesiologia e massoterapia.
- **Studenti universitari.** Il video Atlas è utilizzato in molte classi di anatomia universitarie. I video possono essere compresi senza alcuna conoscenza preliminare di anatomia.

A cosa serve?

- Acland offre una risorsa multimediale che funge da simulatore di anatomia e aiuta gli studenti a testare le proprie conoscenze.
- Fornisci agli studenti contenuti di anatomia di base intuitivi e interattivi con oltre 300 video narrati dal piu' celebre docente di anatomia del mondo.
- Acland presenta esemplari magistralmente sezionati, ruotati di 360 gradi. Non sono stati utilizzati fluidi per imbalsamazione.
- Per gli studenti che non hanno accesso ai laboratori di dissezione, Acland offre l'anatomia della vita reale.
- Consentire agli studenti una visione indipendente e frequente per la revisione, l'autovalutazione e la preparazione pratica all'esame.



5 volumi di Acland

	VOLUME 1 The Upper Extremity	 Take an Exam on The Upper Extremity	
	VOLUME 2 The Lower Extremity	<h3>The Shoulder</h3>	
	VOLUME 3 The Trunk	 1.1.1 Introduction to the shoulder region (0:30)	 1.1.9 Latissimus dorsi, pectoralis major and deltoid muscles (2:48)
	VOLUME 4 The Head and Neck	 1.1.2 The clavicle and scapula (4:11)	 1.1.10 Review of shoulder muscles (1:15)
	VOLUME 5 The Internal Organs	 1.1.3 Movements of the clavicle and scapula (0:59)	 1.1.11 Landmark structures for nerves and blood vessels (2:29)
		 1.1.4 The shoulder joint and its movements (1:43)	 1.1.12 Veins of the shoulder region (3:09)
		 1.1.5 Review of bones, joints, and ligaments of the shoulder (1:17)	 1.1.13 Arteries of the shoulder region (2:35)

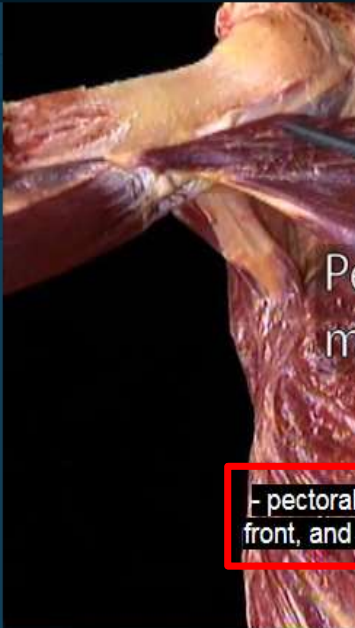
Email e sottotitoli

Volume 1: The Upper Extremity > The Shoulder

1.1.9 Latissimus dorsi, pectoralis major and deltoid muscles

JUMP TO

- Axilla
- Pectoralis major muscle
- Latissimus dorsi muscle
- Deltoid muscle



TRANSCRIPT EMAIL

Email a link to this video

We will email a link to your recipient(s) that is accessible for the next 5 days (and can be clicked on 10 times maximum).

Recipient's Email:



Limited to 5 recipients.
Separate addresses with commas.

Message (optional):

Submit Cancel

Trascrizioni PDF da scaricare

Volume 1: The Upper Extremity > The Shoulder

 TRANSCRIPT  EMAIL

1.1.9 Latissimus dorsi, pectoralis major and deltoid muscles

☰ JUMP TO

- Axilla
- Pectoralis major muscle
- Latissimus dorsi muscle
- Deltoid muscle

1.1.9
Latissimus dorsi, pectoralis major and deltoid muscles
(2:48)

Now we'll complete our picture by looking at three big external muscles: pectoralis major, latissimus dorsi, and deltoid.

Of these, the first two have much in common - pectoralis major on the front, and latissimus dorsi on the back. These two are alike, in that they both pass directly from the trunk to the humerus, bypassing the scapula. Between them they define the posterior and anterior walls of the axilla.

Pectoralis major arises from the medial third of the clavicle, from the front of the sternum, and from the front of the first six costal cartilages. It's inserted here, on the anterior edge of the bicipital groove. Pectoralis major is a powerful adductor of the humerus. When its adducting effect is held in check by other muscles, it also produces internal rotation.

Latissimus dorsi has a very wide origin. It starts here, under the tail end of trapezius, at T7, and goes all the way down to the sacrum, and out onto the posterior iliac crest. It also has some fibers arising from the lower four ribs, and occasionally from the tip of the scapula.

Up Next: 1.1.10 Review of shoulder muscles

Ricerca per parole chiave di video clip

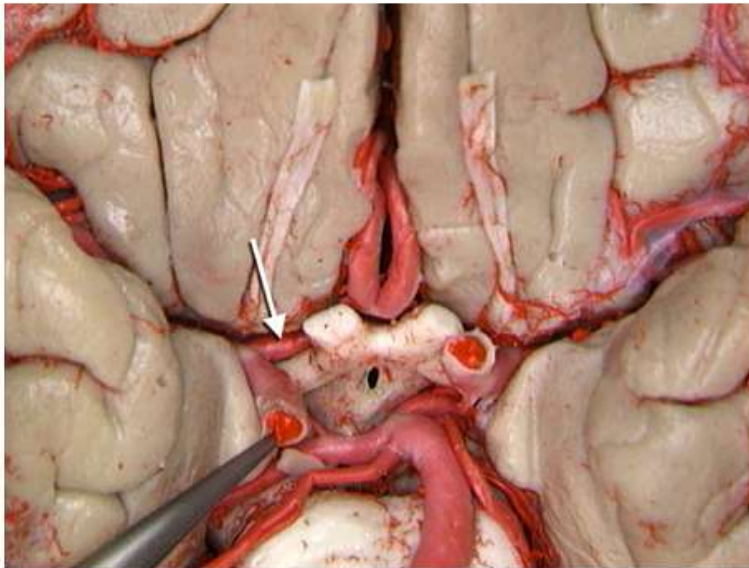
The screenshot displays the website's navigation menu at the top with links for HOME, VIDEOS, EXAMS, GLOSSARY, A-Z INDEX, and ABOUT. Below the navigation, the page title is "Volume 1: The Upper Extremity > The Shoulder" and the main heading is "1.1.9 Latissimus dorsi, pectoralis major and deltoid muscles". A search bar on the right contains the text "knee" and a dropdown menu lists suggestions: "knee joint", "knee region", "knee flexion", "knee joint capsule", "knee joint extensor", and "knee meniscus". The search results for "knee meniscus" are shown in a white box, indicating "Showing 1 - 4 of 4" results. The first result is "2.2.2 Cartilages and cruciate ligaments of the knee joint (3:48)", which includes a small image of a knee joint and a description of fibrocartilage. The second result is "2.2.4 Review of bones and ligaments of the knee joint (1:37)", which includes a "REVIEW" button and a description of the patella and various ligaments. The background of the page features an anatomical illustration of the pectoralis major muscle.

Volume 4: The Head and Neck

[Save Exam & Review Later](#)



0 Incorrect | 0 Correct | 60 Unanswered



Identify the structure indicated.

- A Anterior cerebral artery
- B Internal carotid artery
- C Middle cerebral artery
- D Posterior cerebral artery
- E Posterior communicating artery

[Submit & View Next Question](#)

[Skip & Answer Later](#)

[Save Exam & Review Later](#)

Glossario e indice A-Z

Home VIDEOS ^ EXAMS GLOSSARY **A-Z INDEX** ABOUT

Glossary

Many anatomic structures are still known by names given when Greek, Arabic and Latin were languages. Most anatomic names, so these interesting links with the past remain in service.

type to filter Jump to: [A](#) [B](#) [C](#) [D](#) [E](#) [F](#) [G](#) [H](#) [I](#) [J](#) [K](#) [L](#) [M](#) [N](#) [O](#)

Term	Origin	Meaning
Abduct	LATIN	<i>ab</i> , away + <i>ducere</i> , pull.
Acetabulum	LATIN	<i>acteum</i> , vinegar + <i>abrum</i>
Adduct	LATIN	<i>ad</i> , towards + <i>ducere</i> , pu
Adrenal	LATIN	<i>ad</i> , toward + <i>ren</i> , kidney
Ala (alar)	LATIN	<i>ala</i> , wing.

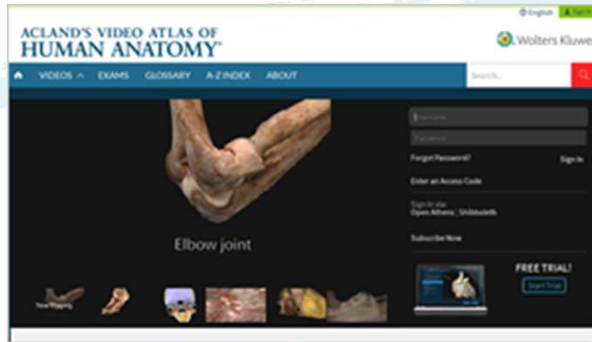
Home VIDEOS ^ EXAMS **GLOSSARY** A-Z INDEX

A-Z INDEX

type to filter JUMP TO: # [A](#) [B](#) [C](#)

- A
- [abdomen](#)
- [abdominal arteries](#)
- [abdominal cavity](#)
- [abdominal muscles](#)
- [abdominal veins](#)
- [abducent nerve](#)
- [abductor digiti minimi muscle](#)

Video e manuale per l'utente



Il video-tutorial in Italiano



Il manuale PDF in Inglese

Videos of Volume 1: The Upper Extremity	
The Shoulder	
1.1.1	Introduction to the shoulder region http://aclandanatomy.com/MultiMediaPlayer.aspx?multimediaid=10528031
1.1.2	The clavicle and scapula http://aclandanatomy.com/MultiMediaPlayer.aspx?multimediaid=10528032
1.1.3	Movements of the clavicle and scapula http://aclandanatomy.com/MultiMediaPlayer.aspx?multimediaid=10528035
1.1.4	The shoulder joint and its movements http://aclandanatomy.com/MultiMediaPlayer.aspx?multimediaid=10528039
1.1.5	Review of bones, joints, and ligaments of the shoulder http://aclandanatomy.com/MultiMediaPlayer.aspx?multimediaid=10528043
1.1.6	Introduction to shoulder muscles http://aclandanatomy.com/MultiMediaPlayer.aspx?multimediaid=10528037
1.1.7	Muscles passing from the scapula to the humerus http://aclandanatomy.com/MultiMediaPlayer.aspx?multimediaid=10528045
1.1.8	Muscles passing from the trunk to the scapula http://aclandanatomy.com/MultiMediaPlayer.aspx?multimediaid=10528049
1.1.9	Latisimus dorsi, pectoralis major and deltoid muscles http://aclandanatomy.com/MultiMediaPlayer.aspx?multimediaid=10528044
1.1.10	Review of shoulder muscles http://aclandanatomy.com/MultiMediaPlayer.aspx?multimediaid=10528051
1.1.11	Landmark structures for nerves and blood vessels http://aclandanatomy.com/MultiMediaPlayer.aspx?multimediaid=10528047
1.1.12	Veins of the shoulder region http://aclandanatomy.com/MultiMediaPlayer.aspx?multimediaid=10528055
1.1.13	Arteries of the shoulder region http://aclandanatomy.com/MultiMediaPlayer.aspx?multimediaid=10528053
1.1.14	Nerves of the shoulder region: the brachial plexus http://aclandanatomy.com/MultiMediaPlayer.aspx?multimediaid=10528059
1.1.15	Review of blood vessels and nerves of the shoulder region http://aclandanatomy.com/MultiMediaPlayer.aspx?multimediaid=10528057
The Arm and Forearm	
1.2.1	Introduction to the arm and forearm http://aclandanatomy.com/MultiMediaPlayer.aspx?multimediaid=10528061
1.2.2	Bones of the arm and forearm http://aclandanatomy.com/MultiMediaPlayer.aspx?multimediaid=10528066
1.2.3	The elbow joint http://aclandanatomy.com/MultiMediaPlayer.aspx?multimediaid=10528071
1.2.4	The distal radio-ulnar joint http://aclandanatomy.com/MultiMediaPlayer.aspx?multimediaid=10528067
1.2.5	The wrist joint http://aclandanatomy.com/MultiMediaPlayer.aspx?multimediaid=10528069
1.2.6	Review of bones, joints, and ligaments of the arm and forearm http://aclandanatomy.com/MultiMediaPlayer.aspx?multimediaid=10528065
1.2.7	Muscles that move the elbow http://aclandanatomy.com/MultiMediaPlayer.aspx?multimediaid=10528072
1.2.8	Muscles that rotate the forearm http://aclandanatomy.com/MultiMediaPlayer.aspx?multimediaid=10528073
1.2.9	Muscles that move the wrist http://aclandanatomy.com/MultiMediaPlayer.aspx?multimediaid=10528077
1.2.10	Review and overview of muscles of the arm and shoulder http://aclandanatomy.com/MultiMediaPlayer.aspx?multimediaid=10528079
1.2.11	Arteries and veins of the arm http://aclandanatomy.com/MultiMediaPlayer.aspx?multimediaid=10528081
1.2.12	Nerves of the arm http://aclandanatomy.com/MultiMediaPlayer.aspx?multimediaid=10528083
1.2.13	Review of blood vessels and nerves of the arm and forearm http://aclandanatomy.com/MultiMediaPlayer.aspx?multimediaid=10528085
---	---

Le URL dei singoli videoclip